

Overuse injuries in Australian Rules football

ADAM CASTRICUM MB BS

Series Editor **KEN CRICHTON** MB BS(Hons), FACSP

The dynamic game of Australian Rules football can put players at risk of overuse injuries. Here we discuss two injuries that commonly lead to time off the playing field.

Australian Rules football – or AFL – is a fast paced game that places extraordinary physical demands on the body. Each game lasts approximately two hours, over half of which time players are either running or sprinting. During a game, players jump, ‘mark’, tackle, handball and kick the ball, placing particular stress on the lower limbs. As a result a range of injuries including traumatic and overuse injuries can occur. Some of these injuries are listed in Table 1.

The enormous amount of running that players undertake throughout the season adds to the stress placed on the lower limbs and also increases their susceptibility to injury. The groin and hip joints are also exposed to increased load and risk of injury due to the large amount of kicking and rapid directional changes associated with play known as ‘cutting’. Further, rapid changes in acceleration place the hamstrings under great strain. In terms of incidence, number of games missed and injury recurrence, hamstring strains and osteitis pubis are the two most common chronic overuse injuries in AFL and are the subject of this article.

Hamstring strains

Due to the high volume of running in AFL and the long kicks associated with play, often required at full speed, players’ hamstrings are placed under immense load, often in a fatigued state. Ham-string injuries are the number one injury in AFL, accounting for 12 to 16% of injuries and an average 18 days of lost training or three games missed per injury.¹ Perhaps more alarming is the injury recurrence rate of 34%, which highlights the necessity of correct diagnosis and management. In addition, a structured physiotherapy program and a gradual sports specific running program are needed for a successful return to sport.

Table 1. Injuries often seen in AFL players¹

Traumatic

Head

- Concussion

Upper limb

- Shoulder sprain or subluxation or dislocation
- Acromioclavicular joint sprain
- Forearm or wrist or hand fracture

Chest

- Rib bruising or fracture

Lower limb

- Contusion
- Anterior cruciate ligament or medial collateral ligament tears
- Ankle sprain

Overuse

Groin

- Osteitis pubis (pubic bone overload)
- Adductor strain or tendinosis or enthesopathy
- Hip joint synovitis, labral tear

Lower limb

- Achilles tendinosis
- Navicular stress fracture

Players at risk

Hamstring strains are more common in players who are older than 23 years, are aboriginal or play with tight quadriceps and/or hamstrings. Players with a history of injury to the hamstring, calf or strained quadriceps are also at greater risk of hamstring injury.^{2,3} The most common site for strain is at the musculotendinous junction, usually in the more lateral biceps femoris. The injury is more likely to occur when training and playing increase in intensity or volume and is thought to occur just before footstrike in the gait cycle, when the hamstring is at its greatest length under the greatest load. Towards the end of a game and the end of a season are also times when players may be at greater risk for this injury, possibly contributed to by neuromuscular fatigue.

Dr Casticum is Sports Physician Registrar, Albert Park Sports Medicine Centre, Albert Park and Lifecare Sports Medicine Centre, Prahran, Vic. He is also the Medical Officer for the Under 19 Australian Institute of Sport Australian Athletics Squad and former Assistant Medical Officer for the Sydney Swans AFL Club. He is also former Academy Medical Officer, AFL NSW/ACT as part of Australasian College of Sports Physicians Registrar Training Program.
Series Editor: Dr Crichton is Director of Sports Medicine at North Sydney Orthopaedic and Sports Medicine Centre, and a Consultant Sports Physician at the Children’s Hospital Institute of Sports Medicine, Westmead, Sydney, NSW.

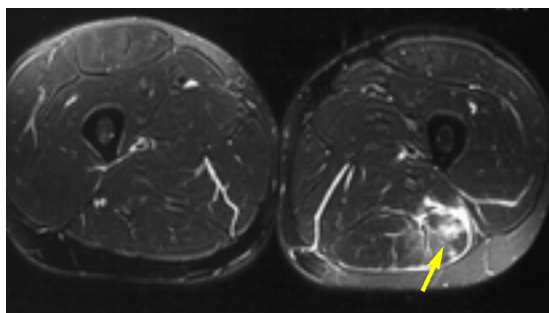


Figure 1. Axial MRI scans of both thighs showing increased muscle oedema in the left biceps femoris consistent with strain of the muscle (arrow). Clinically, this patient had a grade 2 left biceps femoris strain.

Presentation

Players commonly present with posterior thigh pain brought on suddenly by sprinting or bending to pick up the ball. On examination, they may have visible bruising to the posterior thigh and an antalgic gait. Point tenderness with loss of strength and restriction of movement on knee extension with the hip flexed to 90 degrees indicates a likely hamstring strain.

Table 2. Grading of hamstring strains

Grade 1

Minor swelling or discomfort with minimal or no loss of strength and range of movement

- Corresponds to a minor tear or strain where ultrasound or MRI scan is positive
- If imaging results are negative the pain is usually referred from the lumbar spine and/or gluteal trigger points

Grade 2

Swelling and discomfort with loss of strength and range of movement

- Corresponds to a moderate tear

Grade 3

Swelling with minimal discomfort and total lack of muscle function

- Corresponds to a full thickness tear and also avulsion of the entire hamstring off the ischial tuberosity

Diagnosis

Although the diagnosis is clinical, it should be differentiated from referred pain from the lumbar spine or gluteal trigger points. Injury to these areas should be suspected when gait is relatively unaffected, swelling and bruising are absent or the player reports vague tenderness with power maintained despite minimal reduction in straight leg raising range of movement. Neural slump testing will frequently be positive.

In the community setting, the diagnosis should be clinical. Further imaging is not essential, but in the hands of skilled radiologists, ultrasound or MRI can confirm a hamstring tear (Figure 1). Hamstring strains are graded according to severity (Table 2), and if imaging is negative, referred pain from the lumbar spine or gluteal trigger points should be suspected.⁴

Management

Treatment consists of early protection of the strain with regular icing (for 10 minutes every hour for the first 48 hours), use of an elastic compression bandage over the injured area, analgesia using paracetamol and active pain-free extension. NSAIDs should be avoided in the first 48 hours after injury to allow time for the laying down of fibroblasts at the site of the injury and to allow new collagen and muscle fibre synthesis to occur. Studies have shown that using NSAIDs after a strain provides no additional benefit over treatment with physiotherapy alone.⁵

Rehabilitation

Once the pain and inflammation have settled, a structured physiotherapy program should be commenced, aiming at returning full pain-free range of motion and full hamstring strength. An eccentric strengthening program, which involves lengthening the muscle through the range of movement under constant resistance, should be used to maximise gains. A progressive running program can be instituted as soon as the gait pattern normalises, often by the third day after the injury. Massage should be avoided until five days after the injury to reduce the risk of secondary haemorrhage and calcification within the muscle.

It is important that treatment does not only focus on the hamstring muscle. One study showed that a rehabilitation program incorporating progressive agility with trunk stability exercises was far superior to static stretching, isolated progressive hamstring resistance exercise and adding ice to the injury.⁶ Any neural tension from the lumbar spine or gluteal trigger points should be addressed with soft tissue massage, dry needling and neural stretches. Coexisting lumbopelvic strength and stability problems should also be treated with specific core stability physiotherapy exercises.

Return to sport

Injured players can cross train by either riding a bike or swimming to maintain their fitness while recovering from injury. Once symmetrical muscle strength and full range of movement have returned, and players have completed a progressive running program, they can resume sports specific exercises under the supervision of a physiotherapist. Successful completion of a full week of training is suggested prior to return to full competition.

Players who have a grade 1 strain with imaging or clinical evidence of a strain, can usually return to playing football after around three weeks. Interestingly,

those who have a grade 1 strain with negative imaging may return to playing after about a week with appropriate physiotherapy addressing the lumbar spine, gluteal trigger points, neural stretching and lumbopelvic stability.⁴ Larger tears take longer to rehabilitate, and large proximal grade 3 tears may require surgery. In adolescents, an avulsion of the hamstring off the ischial tuberosity requires surgical reattachment if more than a 2 cm displacement is observed on plain x-ray.

Most importantly, players returning from a hamstring injury should continue their core stability exercises and hamstring eccentric strengthening and stretching program. This is because the risk of recurrence is as high as 25% in the three months after return to full competition due to the subtle strength deficits and/or biomechanical compensations in place after injury.⁶ In the community setting, recurrence is often due to an inadequate physiotherapy program; players with a recurrence should be referred to a specialist sports medicine centre.

Osteitis pubis – pubic bone overload

Osteitis pubis has traditionally been referred to as an ‘inflammatory’ condition of the pubic symphysis, the adjoining pubic bones and the associated periosteum. The condition was initially described as occurring postpartum, following surgery or after acute trauma. More recently, osteitis pubis has been used to describe a syndrome of exercise-related groin pain associated with x-ray and bone scan imaging changes in athletes.⁵

Recent research has now shown that the bone is not inflamed in osteitis pubis as previously thought, but the condition demonstrates evidence of a stress reaction similar to that seen in a stress fracture.⁷ The term pubic bone overload is now being used increasingly by sports physicians to describe the condition.

Players at risk

Pubic bone overload is a debilitating injury that can often cause affected players to miss a large portion of the season. In AFL, it is the second most common reason for games missed.¹ It is common among players aged 16 to 25 years, during which time the secondary bony ossification centres of the pubic bone appear and fuse. Pubic bone overload often accompanies a rapid increase in the amount and intensity of training, and is therefore particularly prevalent in players who have moved up a grade or resume preseason training.

Interestingly, in footballers, pubic bone overload is thought to be an end stage condition that often coexists with other preceding overuse pathologies around the hip and groin region (Table 3).^{8,9} Early recognition of these pre-existing conditions together with appropriate management can often prevent pubic bone overload from developing.

Presentation

Pubic bone overload often starts as vague groin pain, tends to be aggravated by running and does not always appear on the side of the player’s kicking leg. The area is often stiff and sore first thing in the morning and tends to warm up with activity. Often the player will notice a decline in performance, especially running speed or kicking distance. If left untreated, bilateral groin pain may develop and often

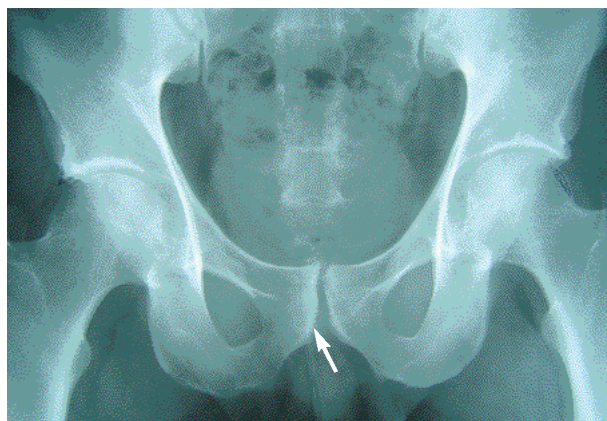


Figure 2. Anterior-posterior pelvic x-ray showing mild sclerosis with ‘moth eaten’ appearance of the right pubic bone (arrow). Such x-ray changes are common in asymptomatic athletes and x-ray should not be solely used for diagnosing pubic bone overload.

Table 3. Overuse conditions of the hip and groin

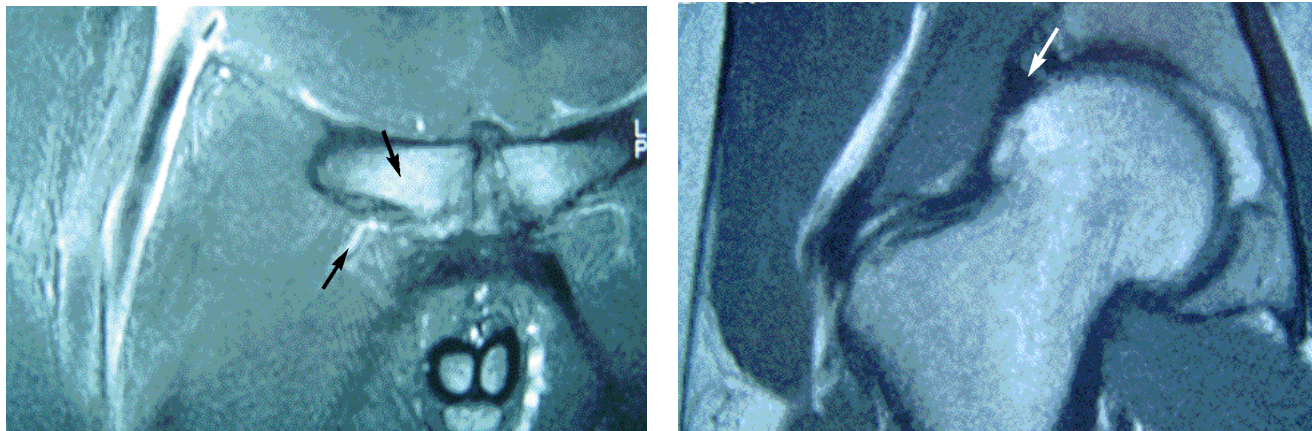
- Adductor strain, tendinosis, enthesopathy or neuromyofascial tightness
- Hip joint synovitis, labral tear
- Iliopsoas tendinosis, bursitis, neuromyofascial tightness
- Pelvic or femoral neck stress fractures
- Rectus abdominus tendinosis
- Conjoint tendon tendinosis
- Referred pain from lumbar spine or sacroiliac joint

rest and night pain eventuates, leading to a further rapid decline in performance preventing the player from playing.

Examination findings are often non-specific, but commonly vague pubic bone tenderness and a reduction in hip internal rotation range of movement are present. Adductor tightness and pain and weakness on the adductor squeeze test can also be evident.

Diagnosis

There is no gold standard investigation for pubic bone overload as the diagnosis is essentially clinical. Diagnosis can be confirmed using a pelvic x-ray and bone scan (Figure 2). Importantly, this will rule out any stress fractures of the pelvis or



Figures 3a and b. a (left). Coronal MRI scan of the pubic bones showing relatively increased bone oedema in the right pubic bone consistent with pubic bone overload (upper arrow). Also note the coexisting longitudinal partial tear of the proximal right adductor longus and associated enthesopathy and the pubic bone-tendon interface (lower arrow). b (right). Coronal MRI scan of the right hip joint in the same patient with an anterosuperior acetabular labral tear. Most of this patient's groin symptoms settled following an ultrasound guided right hip joint cortisone/marcaine injection, allowing him to complete a full physiotherapy program and return to playing high level AFL.

femoral neck. MRI should be only used to assess for other clinically relevant pathologies as signs of pubic bone overload on MRI are often evident in asymptomatic athletes.¹⁰ MRI will show increased bone oedema in the pubic bone and often other coexisting soft tissue pathologies (Figure 3a and 3b).

Management

As pubic bone overload is in essence a stress response of bone to overloading, it should be managed with a significant reduction in load, which may require complete rest from aggravating activities such as running and kicking, and possibly even swimming and cycling, for up to six weeks or until the player can perform exercise without pain. Daily icing and analgesia using paracetamol and/or NSAIDs should also be instituted when managing players with pubic bone overload. Associated contributing pathologies must also be addressed to reduce the sources of load on the pelvis.

Rehabilitation

The cornerstone of treatment is a structured physiotherapy program emphasising core strengthening of transverses

abdominus, multifidus and gluteal muscles to ensure optimal core and lumbopelvic stability. A structured physiotherapy program will also reduce shear forces through the pubic symphysis, as well as the appropriate strengthening of the local musculature, including eccentric strengthening of the adductor muscles.¹¹ This program should be maintained throughout the player's career.

Return to sport

Once the injured player is pain free and has full adductor and core strength, gradual resumption of sport-specific activities can be instituted. This should start with light running, progressing to kicking, cutting and jumping, before playing under the guidance of the team physiotherapist or doctor. Return to playing a full game may take three to four months.

Should other critical pathologies in the region be suspected, or if players are not responding to the above physiotherapy program, they may require referral to a sports physician for further treatment. Late diagnosis and poor management often lead to chronic cases that become resistant to treatment and can

spell the end of otherwise promising football careers. With improved education and early detection of pubic bone overload and its associated conditions, this injury can be treated successfully allowing players a full return to football.

Conclusion

AFL is a fast paced, increasingly popular sport that places great strain on the lower limb as players aim to run faster and further and to kick more goals over longer distances. Pubic bone overload and hamstring strains are common injuries in AFL footballers that require early, accurate diagnosis. Once diagnosed, players with such injuries can then be directed to an appropriately structured rehabilitation program allowing a successful return to the football field. Such programs not only minimise the number of missed games, they can also prevent recurrence of the injury and reduce the change of a chronic injury occurring which may seriously curtail a playing career. **MT**

A list of references is available on request to the editorial office.

DECLARATION OF INTEREST: None.